



Progesterone Levels and Vaginal Cytology in Relation to Canine Ovulation Timing

TARGET
CANINE OVULATION TIMING
the test veterinarians trust


Supplied by:

Vetlab Supplies Limited
Pulborough West Sussex RH20 2RY
Tel: 01798 874567 Fax: 01798 874787
Email: info@vetlabsupplies.co.uk

For further details please phone 01798 874567
or visit our website www.vetlabsupplies.co.uk

A Early Proestrus

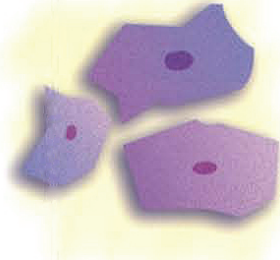
Composed of parabasal cells, small and large intermediate cells; a few superficial cells.



A

B Late Proestrus

Predominantly superficial cells and medium to large intermediate cells. The edges are straight and the cells are flattened.



B

C Estrus

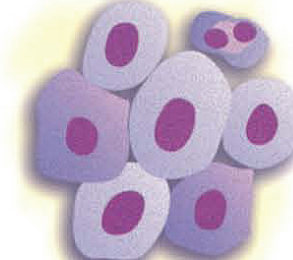The cells are fully cornified.



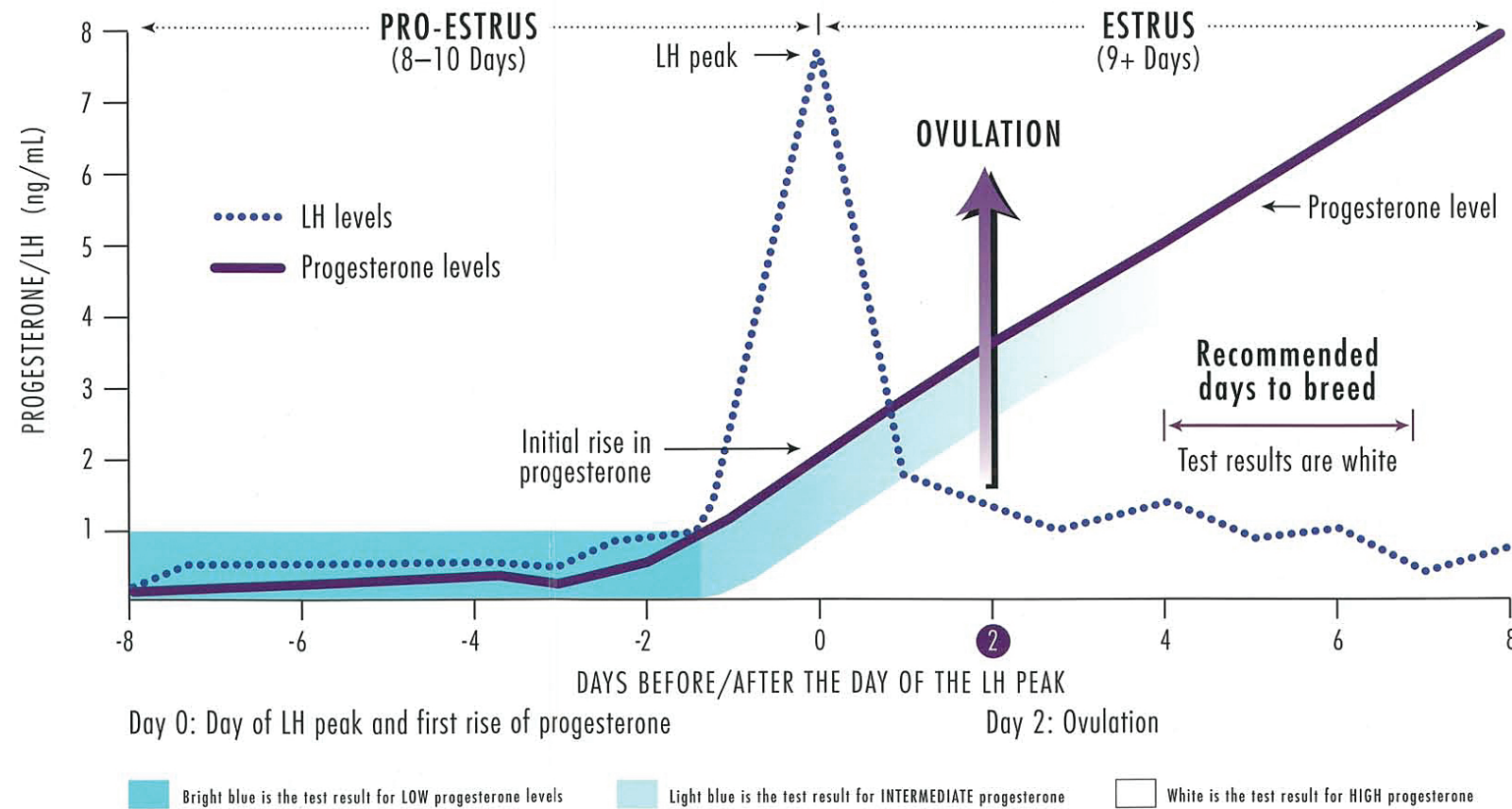
C

D Diestrus

Onset of diestrus is characterized by the sudden appearance of parabasal cells; a change from predominantly cornified to predominantly noncornified.



D




Types of Cells



Parabasal Cells

Round or oval, large nucleus.



Small Intermediate Cells

Slightly larger than parabasal cells, borders irregular.



Large Intermediate Cells

Large cells with irregular borders.



Superficial Cells

Largest cell seen; borders irregular, no nucleus present (fully cornified cells).



Metestrus Cells

Parabasal cells with infiltration of a varying number of nucleated cells.